



श्री मान अध्यक्ष
 साई किरण सोशल वेलफेयर
 सोसाइटी A/75 फ्रीडम
 फाइटर इन्कलेव नेव सराय
 नई दिल्ली - 110068

विषय - मरीज ब्लो इन्फेक्शन मरीना 19 दिन हार्ट
 सर्जरी के सम्बन्ध में

महोदय .

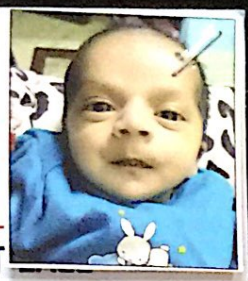सविनय निवेदन यह है कि प्रार्थी एवं
 स्वर्णलाल निवासी A-579 जज कॉलोनी ख्याला
 का रहने वाला हूँ मेरे बेटे ब्लो इन्फेक्शन का
 हार्ट का ऑपरेशन होना है जिसका डॉक्टर का
 स्वयं डॉक्टर ने लगभग 45000 रूपये बताया है और अस्माइलाज
 और गंगा राम अस्पताल में चल रहा है मैं
 धराने का पैसे का फेरी का काम करना हूँ मेरी
 मासिक आय 8,000 रूपये है मैं अपने बेटे का इलाज
 कराने में असमर्थ हूँ।
 अतः आप से निवेदन है कि मेरे बेटे की हार्ट का
 ऑपरेशन कराने में मदद करे
 धन्यवाद

प्रार्थी
 एवं स्वर्णलाल
 A-579 जज Colony Khayala



Sir Ganga Ram Hospital

Department of Pediatric Cardiac Sciences



DR. NEERAJ AGGARWAL

MD, (Peds), FNH, RGHHS (Pediatric Cardiology)
Consultant Pediatric Cardiologist
Mobile : 9818991620
E-mail : drneeraj_12@yahoo.co.in
DMC Regn No. : 25394

Dr. MRIDUL AGARWAL

MD (Peds), FNB (Pediatric Cardiology)
Consultant Pediatric Cardiologist
Mob. : 9873850421
E-mail : drmridul@hotmail.com
DMC Regn No. : 35769

Dr. PRANEET

MD (Peds), FNB (Pediatric Cardiology)
Associate Consultant Pediatric Cardiologist
Mob. : 9953733335
E-mail : praneet1983@gmail.com
DMC Regn No. : 56732

Date: 17.03.2018


To
The President
Sai Kiran Social Welfare Society
A1 /75 1st Floor Freedom Enclave, Neb Sarai
New Delhi - 110068

Dear Sir / Madam

The patient B/o Shivani 1months 17 Days old S/o. Mr. Harsh R/o.H. No-A- 579 J.J. Colony Khayala New Delhi. has been examined by us. He has congenital heart disease, which requires urgent open heart surgery. Patient is planed for admission on 01.04.2018 and surgery on 02.04.2018. The total cost of procedure will be approximately Rs.4, 50,000/- (Four Lakh Fifty Thousand Only).

Please do not hesitate to clarify anything in this regard.

Regards,


Dr. Neeraj Aggarwal
MD (peds), FNH RGHHS (Pediatric Cardiology)
Consultant Pediatric Cardiologist

Dr. NEERAJ AGGARWAL
MD (PEDI) FNH, RGHHS (PED. CARD)
DMC-25394
CONSULTANT PEDIATRIC CARDIOLOGIST
DEPTT. & PEDIATRIC CARDIAC SCIENCES
SIR GANGA RAM HOSPITAL
NEW DELHI-110 060

Rajinder Nagar, New Delhi-110060

OPD Room No. F-57 Timings : 11.00 to 4.00 p.m. Monday to Saturday Ph. : 42251757 (For Appointment) 9873818788



Sir Ganga Ram Hospital

Department of Pediatric Cardiac Sciences



DR. NEERAJ AGGARWAL

MD, (Peds), FNH, RGUHS (Pediatric Cardiology)
Consultant Pediatric Cardiologist
Mobile : 9818991620
E-mail : drneeraj_12@yahoo.co.in
DMC Regn No. : 25394

Dr. MRIDUL AGARWAL

MD (Peds), FNB (Pediatric Cardiology)
Consultant Pediatric Cardiologist
Mob. : 9873850421
E-mail : drmridul@hotmail.com
DMC Regn No. : 35769

Dr. PRANEET LALE

MD (Peds), FNB (Pediatric Cardiology)
Associate Consultant Pediatric Cardiologist
Mob. : 9953733335
E-mail : praneet1983@gmail.com
DMC Regn No. : 56732

5/3/18

B/O Shwani

Res No: 15151/18
LT 2.9 E

Reg By: Dr Satpally

Cardiac TAPVC with

Grade I IJH on USG.

Go

Echo - PFO 4mm

Cardiac TAPVC

Adv - Neuro opinion → timing/
mode of imaging.

- Follow up w/ly.



Sir Ganga Ram Hospital

Department of Pediatric Cardiac Sciences



DR. NEERAJ AGGARWAL

MD, (Peds), FNH, RGHHS (Pediatric Cardiology)
Consultant Pediatric Cardiologist
Mobile : 9818991620
E-mail : drneeraj_12@yahoo.co.in
DMC Regn No. : 25394

Dr. MRIDUL AGARWAL

MD (Peds), FNB (Pediatric Cardiology)
Consultant Pediatric Cardiologist
Mob. : 9873850421
E-mail : drmridul@hotmail.com
DMC Regn No. : 35769

Dr. PRANEET LALE

MD (Peds), FNB (Pediatric Cardiology)
Associate Consultant Pediatric Cardiologist
Mob. : 9953733335
E-mail : praneet1983@gmail.com
DMC Regn No. : 56732

Case No: 15757/18

Wt 25kg

Biosivani
3 Wks / M

20/2/18

SPO₂ - 80%
HR 160/min
Wt + 2.5kg
with acute

ECHO:-

- Cardiac TAPUR
- PFO 4mm
- Dilated RARV

dx

weekly Follow up

Calcicoid drop

o-Sul SAD

PSEB 15/11/18

26/2/18

Echo -

- PFO hum
- Cardiac TAPVC

SpO₂ 78%

HR 184/min

wt 2.7g

Also wble fall aw up

flu

Dr. Raja Joshi

MBBS, MS, MCh, (CTVS)
Fellowship (Cleveland Clinic, USA)

Senior Consultant Neonatal & Pediatric Cardiac Surgeon
Chairman, Department of Pediatric Cardiac Sciences
Sir Ganga Ram Hospital, New Delhi



Date: 12/03/2018

Patient Name: B/o Shivani

Weight: 3.1 Kg

Referred by: Dr. Satpal Yadav

PCS ID No: 15151/18

Date of Birth: 28.01.2018

Age: 1 Months 11 Days / Sex: M

AVC of Cardiac TAPVR is restrictive HFO

SpO₂ = 86%
HR = 175

* Peds neuro clearance
for AdI IVH
after MRI brain

↓
✓ DONE

AdU

OPD visit on 31/3/18

Admission on 1/4/18 (SUNDAY)

Surgery on 2/4/18

* Feeding well

- Syp Fruped 0.2ml PO BD
- Colicaid drops (0.5ml SOS)
- Burping between feeds

R. Joshi

1/4/18 → 4-4-5 L

8 days

- ICU
- med
- op
- con

4 blood donors

← 2/4/18



www.sgrh.com

Dr. Praveen Kumar

MBBS, (BJMC, PUNE) DNB, DCH (DMC : 55455)

Fellowship Pediatric Neurology

M.I.C.N.A., M.A.A.N.

Consultant Pediatric Neurology

Institute of Child Health,

Sir Ganga Ram Hospital, Rajinder Nagar, New Delhi-110060



Formerly at : DR. RML HOSPITAL, New Delhi • INLAKS & BUDHRANI HOSPITAL, Pune • TATA MAIN HOSPITAL, Jamshedpur

Ph. : 011-2575 0000, 4225 4000, Fax : 011-2586 1002 • E : drpraveensingh31@yahoo.com • M : 9560190542 (DMC : 55455)

① o. Maidol A.

Blo Shirchi

Reg No. - 2246263

DOB. 28/01/2018

Boh Boy

1st child

off. 33.5cc.

2.9cc.s.

RID N. Delhi

5/3/2018

Repts

L.S.C.S.

Olisohadgamita

PT/ ~ 33w/1

2.2cc.s

. MSL

1157 hrs X 100cc

Neonatal 52 - 22

oxygen supp.

N.C. feeds

eyes.

Active

(Alert)

not fix'd | follows

marks on 4 limbs

① FE - Alert

+ tone (RT) side

- fine (N)

PR 4RL

Repts

Cardiac Tapvc c

Grade 2 LVH (UL)

PRV.

not on any AED.

CLINICS :

- Clinic : Sir Ganga Ram Hospital, Pvt. OPD, Room No. F-86, 1st Floor, Timing : 8 a.m. to 10 a.m., Mon to Sat, Tel. : 42254000, 1129, 1130
- Room No. F-57, Timing : 4 p.m. to 6 p.m., Mon, Wed, Sat

MRI BRAIN | scan spine 07.03.18
(I.T.)

Flower

USS. skull
-> cerebellum
-> brain?
17H
(R+) LV
chinko
abdominal USS
- (M)

- Evals stimulator; therapy.

Plan.
BER
[epilepsy Review]

cancelled

14 (H)

cancelled
4 major OFC?

07.03.18

next. | cancelled

Flower



Sir Ganga Ram Hospital

Department of Pediatric Cardiac Sciences



DR. NEERAJ AGGARWAL

MD, (Peds), FNH, RGUHS (Pediatric Cardiology)
Consultant Pediatric Cardiologist
Mobile : 9818991620
E-mail : drneeraj_12@yahoo.co.in
DMC Regn No. : 25394

Dr. MRIDUL AGARWAL

MD (Peds), FNB (Pediatric Cardiology)
Consultant Pediatric Cardiologist
Mob. : 9873850421
E-mail : drmridul@hotmail.com
DMC Regn No. : 35769

Dr. PRANEET LALE

MD (Peds), FNB (Pediatric Cardiology)
Associate Consultant Pediatric Cardiologist
Mob. : 9953733335
E-mail : praneet1983@gmail.com
DMC Regn No. : 56732

MR No. : 001826
Patient Name : PCS ID 15151/18 B/o SHIVANI 2246263
Visit Date : 06-Feb-2018 02:15 PM
Sex & Age : Male (9 Days)
Blood Group : N/A
Contact No. : 9999247807

Reg By Dr Satpal Yadav

Height " Weight Kg BMI

• PRESENT COMPLAINTS

OUTSIDE ECHO SMALL ASD

• DIAGNOSIS

CORONARY SINUS TAPVC

• CLINICAL FINDINGS

ESM, SPO2 86%

• REMARKS / ADVICE

NEED EARLY TAPVC REPAIR IN VIEW OF SMALLISH PFO/ASD

- Syb Vitarova - 1ml -
- Dsap Uis ynovel 2 - 1ml -

• INVESTIGATIONS

ECHO- ALL PULMONARY VEIN TO CORONARY SINUS TO RA UNOBSTRUCTED, PFO SIZE 4-5 MM RIGHT TO LEFT, DILATED RA AND RV.

• NEXT FOLLOWUP

(TO COME FOR FOLLOW UP AS ADVISED OR REPORT ANY ABNORMAL SYMPTOMS.)

7/2/18 → USA → B/L gd I IVH, H/O MSL. + perinatal seizure. as

Syb Fureped 0.1ml OD.

(POWERED BY MDeRx Healthcare Systems pvt. Ltd)
DOL-II

Follow up after 7 days ← PFO/ASD restr
Plain ← Prep MRI
Prep Peds nemo clearance
Prep wait 6 wks if possible otherwise earlier.
RV fi:



Sir Ganga Ram Hospital

Department of Pediatric Cardiac Sciences



DR. NEERAJ AGGARWAL

MD, (Peds), FNH, RGHHS (Pediatric Cardiology)
Consultant Pediatric Cardiologist
Mobile : 9818991620
E-mail : drneeraj_12@yahoo.co.in
DMC Regn No. : 25394

Dr. MRIDUL AGARWAL

MD (Peds), FNB (Pediatric Cardiology)
Consultant Pediatric Cardiologist
Mob. : 9873850421
E-mail : drmridul@hotmail.com
DMC Regn No. : 35769

Dr. PRANEET LALE

MD (Peds), FNB (Pediatric Cardiology)
Associate Consultant Pediatric Cardiologist
Mob. : 9953733335
E-mail : praneet1983@gmail.com
DMC Regn No. : 56732

MR No. : 001826
Patient Name : PCS ID 15151/18 B/o SHIVANI 2246263
Visit Date : 13-Feb-2018 02:07 PM
Sex & Age : Male (16 Days)
Blood Group : N/A
Contact No. : 9999247807

Height	''	Weight	Kg	BMI	0.00
--------	----	--------	----	-----	------

• PAST MEDICAL HISTORY

CASE OF CORONARY SINUS TYPE TAPVC- HAD GRADE 1 IVH ON USG
ON WEEKLY FOLLOW UP TO MONITOR PFO
PLAN FOR MRI AND THEN SX AFTER 6 WEEKS

• PRESENT COMPLAINTS

STABLE

• DIAGNOSIS

CORONARY SINUS TAPVC WITH GRADE 1 IVH

• CLINICAL FINDINGS

SPO2-80% HR-180/MIN

• REMARKS / ADVICE

FOLLOW UP AFTER 1 WEEK

• INVESTIGATIONS

ECHO- CORONARY SINUS TAPVC, PFO 4 MM, DILATED RA AND RV, NO TR

(POWERED BY : MDeRx Healthcare Systems Pvt. Ltd)



Sir Ganga Ram Hospital

Patient Name : B/O SHIVANI
(Last,First) : Age/Sex : 16 Days/M
Reg. No. : 2246263 : Ward No. : CENTRAL
Episode No. : OP07381878 : INVESTIGATION CENTRE
Imaging No. : 8712490-18 : Room No. : /
Location : CENTRAL : Executed On : 13-Feb-18 05:35:41PM
INVESTIGATION CENTRE : Location Type : OPD
Referred By : External Doctor : Dr. Satpal Yadav

Department of Pediatric Cardiac Sciences

Pediatric Echo Report

Indication

Cardiac Position

Abdominal SitusSolitus

Levocardia

Cardiac Segments

Atrial SitusSolitus

D-loop ventricle

AV Concordance

Two Patent AV Valves

VA concordance

Normally related great Arteries

Veins & Atria

Normal Systemic Venous Drainage

4 pulmonary veins to coronary sinus to RA.

Interatrial septum. 4mm PFO (Right to left shunt).

Dilated. RA.

Normal LA Size





Sir Ganga Ram Hospital

Patient Name (Last,First)	: B/O SHIVANI	Age/Sex	: 16 Days/M
Reg. No.	: 2246263	Ward No.	: CENTRAL INVESTIGATION CENTRE
Episode No.	: OP07381878	Room No.	: /
Imaging No.	: 8712490-18	Executed On	: 13-Feb-18 05:35:41PM
Location	: CENTRAL INVESTIGATION CENTRE	Location Type	: OPD
Referred By	:	External Doctor	: Dr. Satpal Yadav

Atrioventricular Canal

Normal Mitral valve

Normal Tricuspid valve

Ventricles

Normal left ventricle

Right ventricle. **Dilated.**

Intact Interventricular septum

Conotruncus

Normal Left ventricular outflow tract and aortic valve.

Normal Right Ventricular outflow tract and pulmonary valve

Great Arteries

Normal Ascending Aorta, arch and descending aorta

No PDA/Coarctation

Confluent branch pulmonary arteries.

Function

Normal RV Function


Normal LV Function

(LVEF=60%)

Effusion

No pericardial effusion





Sir Ganga Ram Hospital

Patient Name (Last,First)	: B/O SHIVANI	Age/Sex	: 16 Days/M
Reg. No.	: 2246263	Ward No.	: CENTRAL
Episode No.	: OP07381878	Room No.	: INVESTIGATION CENTRE
Imaging No.	: 8712490-18	Executed On	: /
Location	: CENTRAL	Location Type	: 13-Feb-18 05:35:41PM
	INVESTIGATION CENTRE		: OPD
Referred By	:	External Doctor	: Dr. Satpal Yadav

Coronaries

Normal Coronary arteries

INTERPRETATION

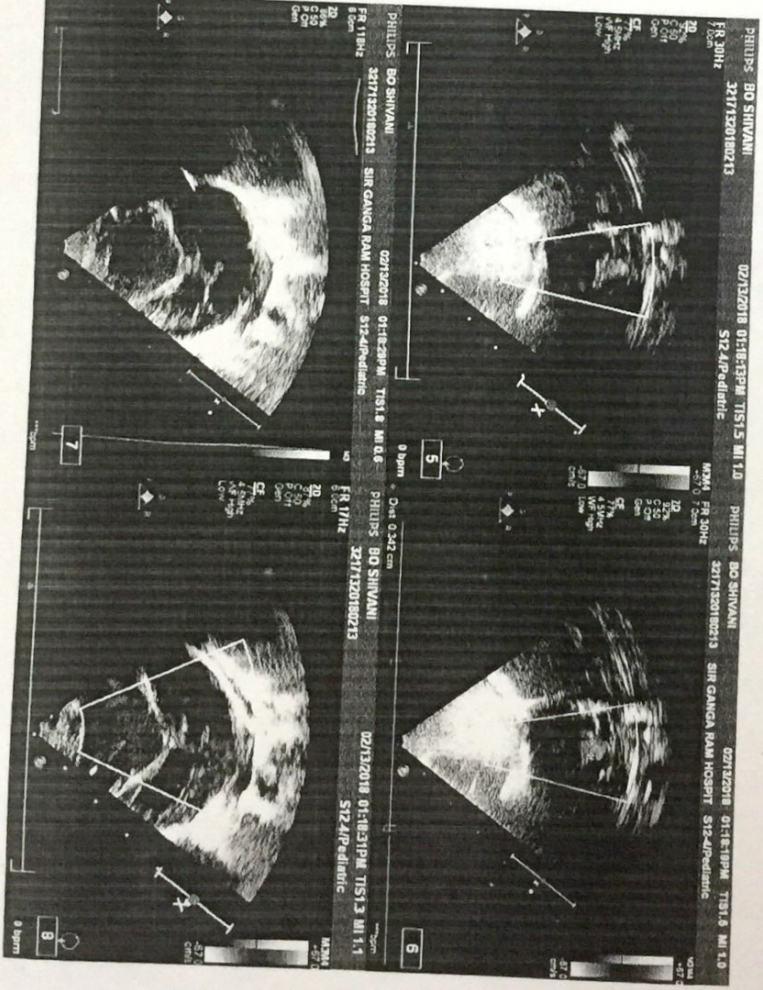
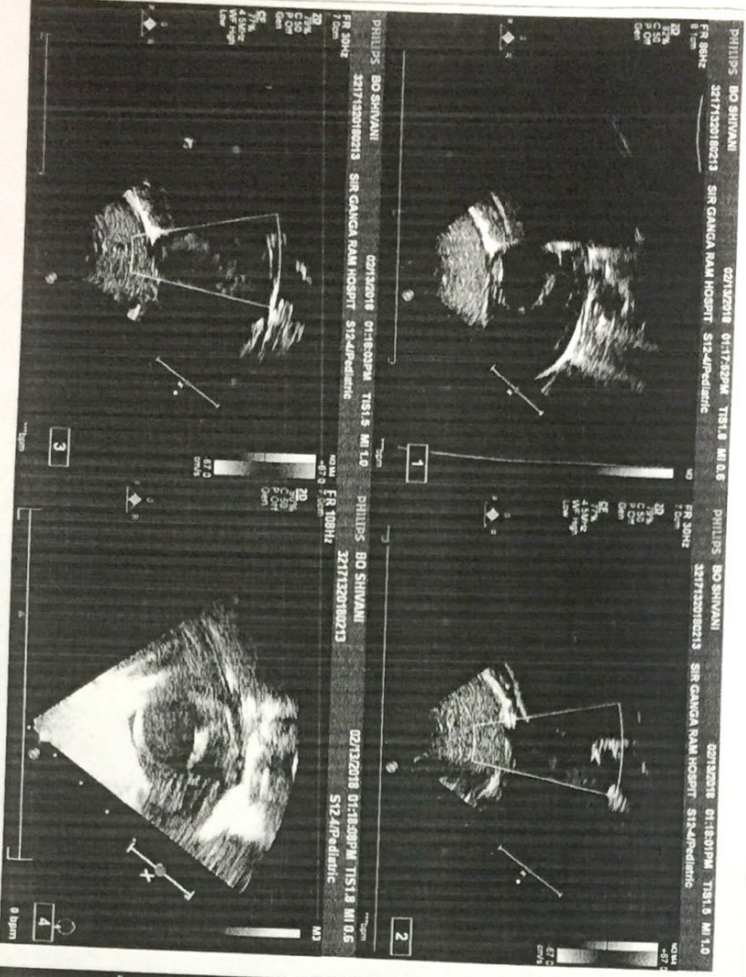
- CORONARY SINUS TAPVC.
- SMALL ASD (RIGHT TO LEFT SHUNT).


DR. NEERAJ AGGARWAL
MD (peds), FNH, RGHHS (Pediatric
Cardiology)
CONSULTANT, PEDIATRIC
CARDIOLOGIST
Sir Ganga Ram Hospital, New Delhi


Dr. MRIDUL AGARWAL
MD (peds), FNB, (Pediatric Cardiology)
CONSULTANT, PEDIATRIC
CARDIOLOGIST
Sir Ganga Ram Hospital, New Delhi

Dr. PRANEET LALE
MD (peds), FNB, (Pediatric Cardiology)
ASSOCIATE CONSULTANT,
PEDIATRIC CARDIOLOGIST
Sir Ganga Ram Hospital, New Delhi







भारत सरकार
 GOVERNMENT OF INDIA



शिवानी खंडेलवाल
Shivani Khandelwal
जन्म तिथि/DOB: 10/07/1993
महिला / FEMALE



8262 6404 8949


आधार-आम आदमी का अधिकार

8262 6404 8949

भारतीय पहचान प्राधिकरण
 UNIQUE IDENTIFICATION AUTHORITY OF INDIA

पता:
W/O हर्ष खंडेलवाल,
ए-579, रीसेटलमेंट
कोलोनी, खयाला, तिआक
नगर, पश्चिम दिल्ली,
दिल्ली - 110018

Address:
W/O Harsh Khandelwal, A-579,
Resettlement Colony, Khayala, Tiak
Nagar, West Delhi,
Delhi - 110018



Aadhaar-Aam Admi ka Adhikar